

MBBS Third Professional Examination

SPECIAL PATHOLOGY

Objectively Structured Performance Evaluation (OSPE)

Model Paper

TOTAL STATIONS=20

TOTAL MARKS: 80 (04 marks per station)

**Time allowed= 01 hour & 20 minutes (04 minutes per
station)**

TABLE OF SPECIFICATION

- 1) SYSTEMIC PATHOLOGY (50% weightage, 10 stations, unobserved)**
- 2) HAEMATOLOGY (25% weightage, 05 stations, unobserved)**
- 3) CHEMICAL PATHOLOGY (25% weightage, 05 stations, unobserved)**

SYSTEMIC PATHOLOGY:

STATION#01 (UNOBSERVED STATION)

For Organizer:

TOPIC SPECIFICATION:

Biliary System (Gall Bladder)

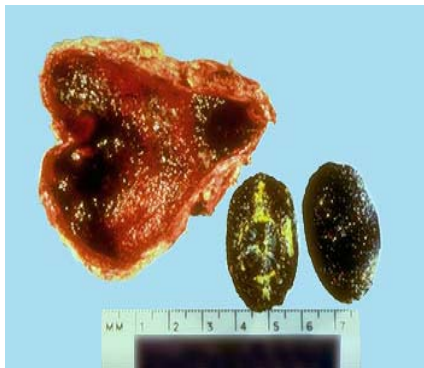SAMPLE MATERIAL:

Gross specimen (or photograph) gall bladder and gall stones.

For Candidate:

Max.Marks: 04

Time Allowed: 04 minutes.



TASK: Carefully examine the given specimen and answer the following questions:

1. Identify the specimen (01)
2. What are the different kinds of stones found in the Gall Bladder?(01)
3. Give the common risk factors for gall stone formation. (02)

For Examiner

Sr.No	KEY	Max.Marks
1.	A specimen of Gall bladder with gall stone /gall stones.	01
2.	a) Cholesterol Stones – 80% b) Pigment stones - 20%	01
3.	a) Ethnic- Geographic factors(cholesterol stones common in Northern Europe, pigment stones common in Asia) b) Age & sex.	02

STATION#02 (UNOBSERVED STATION)

TOPIC SPECIFICATION: Cardiovascular system (Heart)

For Organizer:

SAMPLE MATERIAL:

Clinical Scenario.

A 50 years old male comes to the emergency room with chest pain, sweating and shock like state. He has a family H/O cardiac disease, is a smoker and has raised serum cholesterol level for years.

For Candidate:

Marks: 04

Time Allowed: 04 minutes.

Carefully read the given clinical scenario and answer the following questions:

A 50 years old male comes to the emergency room with chest pain, sweating and shock like state. He has a family H/O cardiac disease, is a smoker and has raised serum cholesterol level for years.

TASK:

1. Give your diagnosis. What are the diagnostic tools available in this case? (02)
2. Give morphological gross picture you will expect in the affected organ at 1-3 days. (01)
3. Give two expected complications in this patient. (01)

For Examiner:

Sr.No	KEY	Max.Marks
1.	Acute myocardial infarction. Available diagnostic tools: 1- ECG. 2- Serum Cardiac Enzymes(CK-MB, TroponinT& I) 3- C-reactive proteins(CRP) 4- Echocardiography.	02
2.	Mottling with yellow tan infarct in the center.	01
3.	1-Arrhythmias 2- Ventricular aneurysm	01

STATION#03(UNOBSERVED STATION)

For Organizer:

TOPIC SPECIFICATION: Breast (Fibro adenoma)

SAMPLE MATERIAL: Microscopic slide of tissue obtained from a lump in the breast of a female patient.

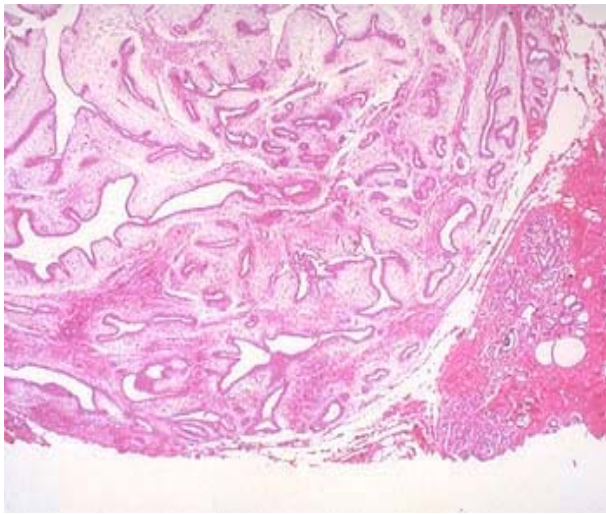
For Candidate:

Marks: 04

Time Allowed: 04 minutes.

TASK:

Carefully examine the focused slide and answer the following questions:



1. Give your diagnosis. (01)
2. Give TWO features of identification (02)
3. Give the main histological patterns (01)

For Examiner:

Sr.No	Key	Max.marks
1.	Fibroadenoma.	01
2.	-Encapsulated benign tumor with desmoplasia . -Slit like and dilated mammary ducts.	02
3.	Intra and periductal patterns.	01

STATION#04UNOBSERVED STATION)

For Organizer:

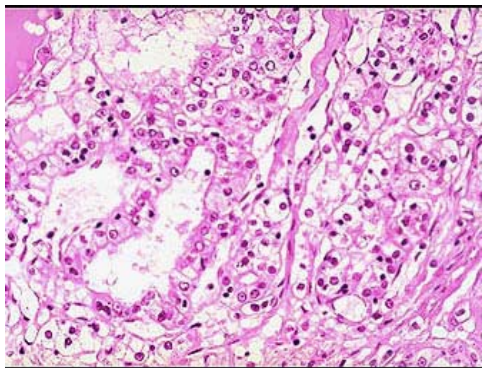
TOPIC SPECIFICATION: Urinary Tract-Kidney (Renal Cell Carcinoma)

SAMPLE MATERIAL: Microphotograph of a lesion in the kidney of a 50 year old male.

For Candidate:

Marks: 04

Time Allowed: 04 minutes.



TASK:

Carefully examine the given photomicrograph and answer the following questions:

1. Identify the lesion. (01)
2. Give three points of identification in favour of your diagnosis. (03)

For Examiner:

Sr.No	Key	Max.Marks
1.	Renal Cell Carcinoma	01
2.	a) Solid to trabecular and tubular patterns.	01
	b) The malignant cells contain abundant clear cytoplasm	01
	c) Delicate branching vasculature	01

STATION#05 (UNOBSERVED STATION)

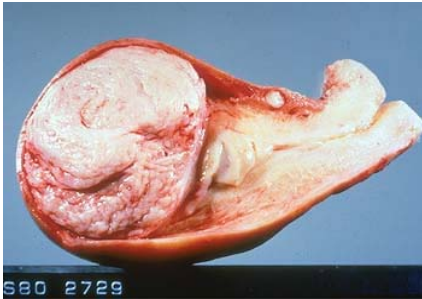
Marks: 04

Time Allowed: 04 minutes.

For Organizer:

**TOPIC SPECIFICATION :) Female Genital Tract (Uterine
Leiomyoma)**

**SAMPLE MATERIAL: Specimen of enlarged bulky
Uterus**



For Candidate:

TASK:

Carefully examine the given specimen and answer the following questions:

- 1. Identify the Specimen and give your diagnosis. (01)**
- 2. Describe the gross appearance of the lesion (01)**
- 3. Give the clinical presentation. (02)**

For Examiner:

Sr.No	Key	Max.Marks
1.	Specimen of Uterus with leiomyoma	01
2.	This very common benign mesenchymal tumour is seen in the uterine wall. They are well circumscribed with a homogeneously white cut surface."Leiomyo" refers to smooth muscle.	01
3.	-Asymptomatic to abnormal bleeding. - Lower abdominal pain- Urinary frequency due to bladder compression-Spontaneous abortion in pregnant women.	02

STATION#06(UNOBSERVED STATION)

For Organizer:

TOPIC SPECIFICATION: Male Genital Tract (prostate)

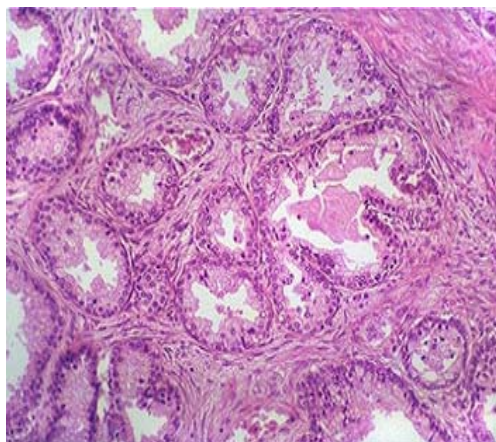
SAMPLE MATERIAL:

Microphotograph of microscopic appearance of a trans urethral resection (TUR) sample of the prostate from a 70 years old male with H/O difficulty in micturation.

For Candidate:

Marks: 04

Time Allowed: 04 minutes.



TASK:

Carefully examine the given microphotograph of microscopic appearance of a trans urethral resection (TUR) sample of the prostate from a 70 years old male with H/O difficulty in micturation and answer the following questions:

1. Give your diagnosis. (01)
2. Examine the slide in the photomicrograph and give three points in favour of your diagnosis. (03)

Sr.No	Key	Max.Marks
1.	Benign Prostatic Hyperplasia.	01
2.	a) Nodules composed of crowded, hyperplastic glands and fibromuscular stroma.	01
	b) Well-circumscribed margin of the process.	01
	c) Two-cell-layer epithelium characteristic of benign prostatic glands	01

STATION#07(UNOBSERVED STATION)

For Organizer:

TOPIC SPECIFICATION: Endocrine System (Thyroid).

SAMPLE MATERIAL: Microscopic slide of a biopsy from a swelling in front of neck in a 30 years old female.

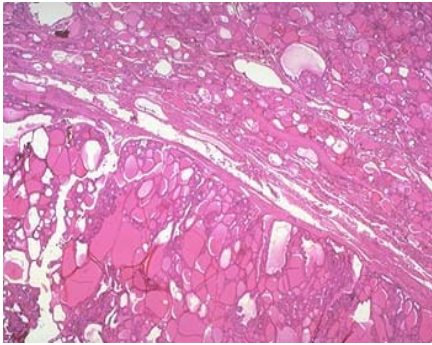
For Candidate:

Marks: 04

Time Allowed: 04 minutes.

TASK:

Carefully examine the focused microscopic slide of a biopsy from a swelling in front of neck in a 30 years old female and answer the following questions:



1. Give your diagnosis. (01)
2. Carefully examine the slide and give three points in favour of your diagnosis. (03)

For Examiner:

Sr.No	Key	Max.Marks
1.	Follicular adenoma of thyroid gland.	01
2.	a) The border between the adenoma and non-neoplastic thyroid tissue is distinct.	01
	b) Multiple colloid filled follicles of variable sizes.	01
	c) Benign cuboidal cells of follicular epithelium.	01

STATION#08(UNOBSERVED STATION)

For Organizer:

TOPIC SPECIFICATION: Bones and joints (Osteosarcoma)

SAMPLE MATERIAL: Clinical Scenario.

A 17 year old male comes to the hospital with history of painful, gradually increasing swelling in the left knee joint, x-ray was ordered and found to have osteolytic and osteoblastic lesions with Codman triangle.

For Candidate:

Marks: 04

Time Allowed: 04 minutes.

TASK:

Carefully read the given clinical scenario and answer the questions:

A 17 year old male comes to the hospital with history of painful, gradually increasing swelling in the left knee joint, x-ray was ordered and found to have osteolytic and osteoblastic lesions with Codman triangle.

1. What is your clinical impression? (01)
2. What can be the major sites of involvement? (01)
3. Give the age incidence and association of the lesion with other conditions. (02)

Sr.No	Key	Max.Marks
1.	Osteosarcoma	01
2.	Knee joint (60%) Pelvis and hip joint (15%) Shoulder joint (10%) Mandible(8%)	01
3.	a) Bimodal age distribution less than 20 years and elderly. b) Paget disease, bone infarcts, and prior irradiation.	02

STATION#09(UNOBSERVED STATION)

For Organizer:

TOPIC SPECIFICATION: Respiratory System (Lung)

SAMPLE MATERIAL: Gross Specimen (or photograph) of lung from a patient living in urban area.

For Candidate:

Marks: 04

Time Allowed: 04 minutes.

TASK: carefully examine the give specimen and:

1. Identify the lesion. (01)
2. Give the pathogenesis of the lesion. (03)

Sr.No	Key	Max.Marks
1.	Anthracosis.	01
2.	a) Commonly seen in urban dwellers and tobacco smokers.	01
	b) Inhaled carbon pigment is engulfed by alveolar macrophages.	01
	c) Accumulation of connective tissue along lymphatic and lymphoid tissue along bronchi or lung hilus.	01

STATION#10(UNOBSERVED STATION)

For organizer:

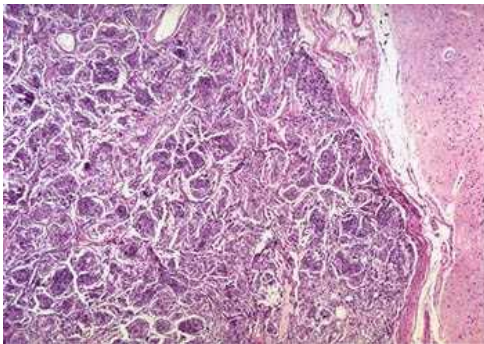
TOPIC SPECIFICATION: Central nervous system: (Brain – Meningioma)

SAMPLE MATERIAL: Microscopic slide of tissue obtained from a space occupying lesion in the brain of a 20 year old male with H/O headache and fits.

For candidate:

Marks: 04

Time Allowed: 04 minutes.



TASK:

Carefully examine the focused microscopic slide of tissue obtained from a space occupying lesion in the brain of a 20 year old male with H/O headache and fits.

1. Give your diagnosis. (01)
2. Give TWO points to support your diagnosis. (01)
3. Name its different histologic patterns. (02)

For Examiner:

Sr.No	Key	Max.Marks
1.	Meningioma.	01
2.	Clusters or whorls of cells and scanty vascular stroma.	01
3.	Syncytial, Fibroblastic, Transitional, Psammomatous, Secretory, Microcystic.	02

HAEMATOLOGY

STATION#11 (UNOBSERVED STATION)

For Organizer:

TOPIC SPECIFICATION:

Acute lymphoblastic leukaemia

SUBJECT MATERIAL: Clinical scenario with Giemsa stained slide of bone marrow.

5-years old child presents with fever, lymph adenopathy and bone pains. LAB. PICTURE: Hb: 8gm/dl, TLC $18,000 \times 10^9/L$, Platelet $80 \times 10^9/L$, Blast cells 15%

For Candidate:

Marks: 04

Time Allowed: 04 minutes.

TASK:

Carefully read the clinical scenario and examine the focused Giemsa stained Bone marrow slide. Answer the following questions:

- 1) Give your findings and diagnosis. (02)
- 2) What stain is indicated to differentiate ALL (Acute lymphoblastic leukaemia) from AML (Acute Myeloid Leukaemia) (02)

For Examiner:

Sr.No	Key	Max.Marks
1.	Replacement of marrow by blast cells. Acute leukaemia	02
2.	Sudan Black, Myelo peroxidase.	02

STATION#12 (UNOBSERVED STATION)

For Organizer:

TOPIC SPECIFICATION:

Iron deficiency anaemia.

SUBJECT MATERIAL: Clinical scenario and Giemsa stained peripheral blood film showing anisocytosis and poikilocytosis.

A 35-years old female gives history of menorrhagia, easy fatigability, and dyspnoea. Her laboratory investigations showed: Hb: 8 gm/dl, TLC $5 \times 10^9/L$, Platelet $490 \times 10^9/L$, MCV: 60 fl, MCH: 20 pg/dl, MCHC: 28 L/L.

For Candidate:

Marks :04

Time Allowed:04 minutes.

TASK:

Carefully read the clinical scenario and examine the Giemsa stained slide of peripheral blood film.

A 35-years old female gives history of menorrhagia, easy fatigability, and dyspnoea. Her laboratory investigations showed: Hb: 8 gm/dl, TLC $5 \times 10^9/L$, Platelet $490 \times 10^9/L$, MCV: 60 fl, MCH: 20 pg/dl, MCHC: 28 L/L.

Answer the following questions:-

- 1) Describe red cell morphology. (01)
- 2) What is the diagnosis? (01)
- 3) Write differential diagnosis. (01)
- 4) Name different tests to confirm diagnosis. (01)

For Examiner:

Sr.No	Key	Max.Marks
1.	Microcytic Hypochromic cells.	01
2.	Iron deficiency anaemia.	01
3.	Anaemia of chronic disorder,Thallasemia, Sidroblastic anaemia.	01
4.	Serum Iron level, Total Iron binding capacity (TIBC), Serum Ferritin level.	01

STATION#13 (UNOBSERVED STATION)

For organizer:

TOPIC SPECIFICATION: Disseminated intravascular coagulation.

SUBJECT MATERIAL: Clinical scenario and Giemsa stained slide of peripheral blood film showing fragmented cells.

A 35-years old female gave history of induced abortion by a 'Dai'. She presented with massive bleeding per vaginum and gangrene of left toe. Her labs are PT: Prolonged, APTT: Prolonged, Fibrinogen: Reduced, Platelet: Reduced.

For candidate:

Marks :04

Time Allowed:04 minutes.

TASK:

Carefully read the clinical scenario and examine the Giemsa stained slide of peripheral blood film.

A 35-years old female gave history of induced abortion by a 'Dai'. She presented with massive bleeding per vaginum and gangrene of left toe. Her labs are PT: Prolonged, APTT: Prolonged, Fibrinogen: Reduced, Platelet: Reduced.

- 1) What is the morphology of red blood cells? (01)
- 2) Give the most likely clinical diagnosis (01)
- 3) Name the type of anaemia associated with this condition? (01)
- 3) What tests will confirm the diagnosis? (01)

Sr.No	Key	Max.Marks
1.	Fragmented red cells.	01
2.	Disseminated intravascular coagulation (DIC).	01
3.	Microangiopathic haemolytic anaemia.	01
4.	D-Dimers and fibrinogen degradation products (FDPs).	01

STATION#14 (UNOBSERVED STATION

For Organizer:

TOPIC SPECIFICATION: Multiple myeloma.

SUBJECT MATERIAL: A photograph of serum electrophoresis and a focused slide of bone marrow along with a clinical scenario.

A 55-year old male presents with fever, weight loss, and bone pains. X-ray shows lytic lesions in the bones. His labs are Hb: 8gm/dl, TLC 3×10^9 L, Platelet 90×10^9 L, ESR 100 mmHg.

For Candidate:

Marks :04

Time Allowed:04 minutes.

TASK:

Read the given clinical scenario and carefully examine the photograph of serum electrophoresis and focused slide of bone marrow.

A 55-year old male presents with fever, weight loss, and bone pains. X-ray shows lytic lesions in the bones. His labs are Hb: 8gm/dl, TLC 3×10^9 L, Platelet 90×10^9 L, ESR 100 mmHg.

Answer the following questions:

- 1) Describe the electrophoresis pattern. (01)
- 2) What is the diagnosis? (01)
- 3) What are Bence jones proteins? (01)
- 4) What are different types of immunoglobulins? (01)

For Examiner:

Sr.No	Key	Max.Marks
1.	Monoclonal spike in gamma region.	01
2.	Multiple myeloma.	01
3.	Kappa light chains in urine.	01
4.	IgM, IgG,IgA, IgD, IgE.	01

STATION#15 (UNOBSERVED STATION:

For Organizer:

TOPIC SPECIFICATION: Blood Grouping

SUBJECT MATERIAL: Test tubes showing agglutination reaction for B+ blood group.

For Candidate:

Marks :04

Time Allowed:04 minutes.

TASK:

Provided are four test labelled A,B,AB,and D.Examine carefully and answer the given questions:

- 1) What is the ABO blood group? (01)
- 2) What is Rh blood group? (01)
- 3) Give the class of antibody formed against ABO blood group antigens? (01)
- 4) Give the class of antibody formed against Rh blood group antigens? (01)

For Examiner:

Sr.No	Key	Max.Marks
1.	ABO Blood group is B.	01
2.	Rh blood group is positive (Rh+).	01
3.	IgM	01
4.	IgG	01

CHEMICAL PATHOLOGY:

STATION#16 (UNOBSERVED STATION)

For Organizer:

TOPIC SPECIFICATION:

Liver and Biliary Tract.

SUBJECT MATERIAL:

Clinical Scenario.

A medical student presents with symptoms of fever, nausea, vomiting, and pain in the right hypochondrium. There is history of passing dark coloured urine.

Liver function tests reveal:

Bilirubin	:	8.5 mg/dl	↑
AST	:	800 u/L	↑
ALT	:	1200 u /L	↑
Alkaline phosphatase:		150 u/L	↑
Total Protein	:	7.5 g /dl	N
Albumin	:	3.8 g/dl	N

For Candidate:

Marks: 04

Time Allowed: 04 minutes.

TASK:

Carefully read the given clinical scenario and answer:

Clinical Scenario.

A medical student presents with symptoms of fever, nausea, vomiting, and pain in the right hypochondrium. There is history of passing dark coloured urine.

Liver function tests reveal:

Bilirubin	:	8.5 mg/dl	↑
AST	:	800 u/L	↑
ALT	:	1200 u /L	↑
Alkaline phosphatase:		150 u/L	↑
Total Protein	:	7.5 g /dl	N
Albumin	:	3.8 g/dl	N

1) What is the diagnosis? (01)

2) Give points that suggest the diagnosis. (01)

3) Which serological viral markers would you like to perform in this case? (02)

For Examiner:

Sr.No	Key	Max.Marks
1.	Acute viral hepatitis	01
2.	Increased bilirubin and transaminase levels	01
3.	Anti-HAV IgM, Anti-HEV IgM, HBsAg and Anti-HCV	02

STATION#17 (UNOBSERVED STATION)

For Organizer:

TOPIC SPECIFICATION:

Diseases of Urinary System.

SUBJECT MATERIAL:

Clinical scenario

A young man sustained multiple injuries in a motorcycle accident. He received multiple blood transfusions and underwent surgery. 24-hours after admission, he had only passed 400 ml of urine, was clinically dehydrated and his blood pressure was 90/50 mmHg.

Lab. investigations:-

Serum: Urea : 150 mg/dl (10-50mg/dl)
 Creatinine : 1.8 mg/dl (0.4-1.4 mg/dl)
 Potassium : 5.6 mmol/L (3.4-5.2 mmol/L)

 Sodium : 132 mmol/L (134-154 mmol/L)

For Candidate:

Marks: 04

Time Allowed: 04 minutes.

TASK:

Carefully read the given clinical scenario and answer the questions:

Clinical scenario

A young man sustained multiple injuries in a motorcycle accident. He received multiple blood transfusions and underwent surgery. 24-hours after admission, he had only passed 400 ml of urine, was clinically dehydrated and his blood pressure was 90/50 mmHg.

Lab. investigations:-

Serum: Urea : 150 mg/dl (10-50mg/dl)
 Creatinine : 1.8 mg/dl (0.4-1.4 mg/dl)
 Potassium : 5.6 mmol/L (3.4-5.2 mmol/L)

 Sodium : 132 mmol/L (134-154 mmol/L)

- 1) What is the diagnosis? (01)
- 2) Why are urea and creatinine levels raised in this patient? (02)
- 3) What lab investigation would you perform to monitor treatment in this patient? (01)

Sr.No	Key	Max.Marks
1.	Acute renal failure	01
2.	Due to hypovolemia and tissue injury.	02
3.	Renal function tests (Urea,creatinine,serum electrolytes).	01

STATION#18 (UNOBSERVED STATION)

For Organizer:

TOPIC SPECIFICATION: ENDOCRINOLOGY

SUBJECT MATERIAL:

Clinical scenario

A 10-years old boy was referred to hospital for investigations of short stature. He had only grown 2 cm in height since the last 2 years. On examination there was no abnormality apart from his short stature.

Lab investigations:-

Serum:

Growth hormone (GH): 4 mU/L (after vigorous exercise)

Growth hormone (GH): 4 mU/L (during documented hypoglycemia induced by insulin)

- Following stress, the level of Growth Hormone Should be more than 20mU/L

For Candidate:

Marks: 04

Time Allowed: 04 minutes.

TASK:

Carefully read the clinical scenario and answer the questions:

Clinical scenario:

A 10-years old boy was referred to hospital for investigations of short stature. He had only grown 2 cm in height since the last 2 years. On examination there was no abnormality apart from his short stature.

Lab investigations:-

Serum:

Growth hormone (GH): 4 mU/L (after vigorous exercise)

Growth hormone (GH): 4 mU/L (during documented hypoglycemia induced by insulin)

- Following stress, the level of Growth Hormone Should be more than 20mU/L

1) What is your diagnosis? Give reason for your diagnosis. (02)

2) Name two other causes of short stature. (02)

For Examiner:

Sr.No	Key	Max.Marks
1.	Dwarfism due to Growth Hormone deficiency. Low serum growth hormone level that did not increase after induced stress.	1+1
2.	Cretinism, malnutrition, achondroplasia.	1+1

STATION#19 (UNOBSERVED STATION)

For Organizer:

TOPIC SPECIFICATION: DIABETES MELLITUS

SUBJECT MATERIAL:

Clinical scenario

A 54-years old man with Diabetes Mellitus is referred to an ophthalmologist for evaluation of developing cataract. Pre-appointment blood work-up showed the following results.

Fasting Blood Sugar: 180 mg/dl
Haemoglobin : 15.0 g/dl
HbA1C : 9.2 %
Urine Glucose : Positive
Urine ketone : Negative

For Candidate:

Marks: 04

Time Allowed: 04 minutes.

TASK:

Carefully read the given clinical scenario and answer the questions:

Clinical scenario:

A 54-years old man with Diabetes Mellitus is referred to an ophthalmologist for evaluation of developing cataract. Pre-appointment blood work-up showed the following results.

Fasting Blood Sugar: 180 mg/dl
Haemoglobin : 15.0 g/dl
HbA1C : 9.2 %
Urine Glucose : Positive
Urine ketone : Negative

- 1) Which investigation best indicates that blood glucose in this patient has been elevated over a period of last few weeks and why? (02)
- 2) Give the normal reference values for fasting plasma glucose and two hours postprandial plasma glucose? (02)

For Examiner:

Sr.No	Key	Max.Marks
1.	HbA1c. Due to increased formation of Glycated Hb over a period of 2-3 months	02
2.	Fasting: 60-110 mg/dl 02 hours postprandial: upto 140mg/dl	01 01

