

Comparison Between Angiographic Findings Of The Coronary Artery Involved In Acute Myocardial Infarction Between Military And Civilian Sectors

Muhammad Ashraf Chaudhry, Hamza Malik, Mujadad Ahmed Khan Niazi, Saeed Arif, Saqib Kirwan Walayat

Abstract

Objective: Comparison between involvement of different coronary arteries in acute myocardial infarction among military and civilian population.

Place: Combined military hospital Lahore and Punjab institute of cardiology Lahore. **Time**

Duration: From 15th March to 15th April 2010.

Study Design: Comparative cross-sectional study.

Patients And Methods: 50 civilians patients admitted in PIC Lahore and 50 patients admitted in CMH Lahore with confirmed acute myocardial infarction on angiography were selected in the study by consecutive sampling.

Results: Involvement of left circumflex coronary artery was documented only in military personnel ($p=.003$), whereas left anterior descending artery was predominantly (64%) involved in civilian population ($p=.091$). Military personnel had more (42%) triple vessel coronary artery disease ($p=.003$) and double vessel coronary artery disease ($p=0.001$) in contrast to civilian population.

Conclusion: Involvement of coronary arteries varies significantly ($p=.000$) among the different sectors of the same society. **Key Words:** Coronary artery; Angiography; Acute myocardial infarction; Military; Civilian.

INTRODUCTION

The fact that with anterior myocardial infarction (MI), the occlusion is nearly always in the left anterior descending coronary artery (LAD), while inferior MI is either due to right coronary artery (RCA) or left circumflex coronary artery occlusion is well established¹.

Coronary angiography is the best means of determining the culprit coronary artery in acute myocardial infarction (AMI)². Identifying the culprit artery in acute myocardial infarction helps to define those in whom aggressive reperfusion strategies are likely to yield the most benefit³. Patients with inferior myocardial infarction (MI) who have right ventricular (RV) myocardial involvement appear to have a worse prognosis than those who do not have RV involvement⁴. The worst prognosis in patients with RV myocardial involvement may be related to the increased risk of life threatening ventricular arrhythmia in these patients⁵. Inferior myocardial infarction accounts for 40%-50% of all acute myocardial infarctions⁶. Although correlation between different

coronary arteries, distribution of myocardial infarctions and prognosis among these patients is well established, we could not find any study demonstrating topography of different coronary arteries in patients having acute myocardial infarction among different sectors of the community. Keeping these points in view we conducted a clinical survey comparing the involvement of different coronary arteries observed in Combined Military Hospital (CMH) Lahore (defense sector) and (PIC) Lahore (public sector).

STUDY OBJECTIVE

A comparison between involvement of different coronary arteries in acute myocardial infarction among defense and civilian population.

METHODOLOGY

Our clinical survey was conducted in the time frame of 1 month (March to April, 2010). The purpose of this survey was to tabulate 100 patients who had suffered from recent myocardial infarction. Fifty patients each

were consecutively selected from CMH (Combined Military Hospital) Lahore, a Military Hospital, and PIC (Punjab institute of cardiology), a public Hospital. Only those patients were taken who had a recent myocardial infarction, within a time period of one month. Angiography report with conclusive result was the most essential criteria and all patients without it or with disputed results were not included in this research. Also all military personnel in PIC and all civilians admitted in CMH were not included as well. There was no age limit imposed. Both genders, male and female, were included in this survey. The survey was conducted with the help of a detailed questionnaire which included the name of the patient, age, gender, bed number, angiography result and occupation. The questionnaire was completed with help of face to face interviews after proper consent of the patient and any family member available. Medical files of the patients were also utilized as assistance. Any unwilling patient was not included in the survey. Computer software program SPSS version 12.0 was used for statistical analysis of data. P value < 0.05 was considered statistically significant.

RESULTS

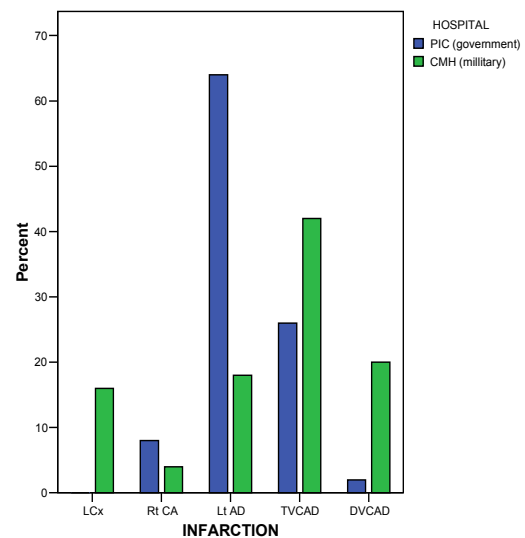
We documented great variation among the involvement of different coronary arteries among civilian and military sectors. Among our two groups 50 adult patients, each from PIC and CMH, left circumflex coronary artery was involved in 16% of the military personnel and 0% in civilian population. Right coronary artery was involved in 4% of the military personnel and 8% of the civilians. Left anterior descending coronary artery was the predominant culprit artery involved in 64% in the civilians and 18% of the military personnel. Triple vessel coronary artery disease (TVCAD) was the culprit artery with an occurrence of 42% in the military personnel in contrast to 26% of the civilians. Double vessel coronary artery disease (DVCAD) was documented in 20% of military personnel and 2% civilian. Chi-Square test was applied to check the significance between the involvement of different coronary arteries in CMH and PIC which

overall showed a strong relationship with a p value of 0.001.(table 1, fig.1).

Table-1
Comparison between angiographic findings of the coronary artery involved in acute myocardial infarction between PIC and CMH Lahore

Coronary artery involved	PIC (Civillian)	CMH (Military)	P-Value	Total
TVCAD (triple vessel coronary artery disease)	13 (26%)	21 (42%)	.003	34 (34%)
DVCAD (double vessel coronary artery disease)	1 (2%)	10 (20%)	0.001	11 (11%)
LCX (left circumflex coronary artery)	0 (0%)	8 (16%)	0.40	8 (8%)
LT Ad (left anterior descending coronary artery)	32 (64%)	9 (18%)	.091	41 (41%)
RT Ca (right coronary artery)	4 (8%)	2 (4%)	0.004	6 (6%)

Figure-1
Comparison of coronary artery involved between CMH Lahore and PIC patients



DISCUSSION

Acute myocardial infarction is usually caused by rupture of unstable plaque and involves coronary artery⁷. We found that single coronary artery was involved in 55% of the patients but it differed in our two groups. It was 72% in the civilian population in contrast to 38% observed in military personnel. Burke and Virmanni found, in autopsy examination of patients who died of acute myocardial infarction that

25-50% had multiple acute coronary thrombosis⁸. Our study showed multiple acute coronary thrombosis (TVCAD and DVCAD) in 45% of the total cases. Similarly using coronary angiography Goldstein et al found that many acute myocardial infarction patients have multiple coronary plaques with overlying thrombi⁹. These multiple thrombi are associated with adverse outcomes¹⁰. Simultaneous formation of the thrombi in two different coronary arteries is very rare¹¹ and acute obstruction of the left main coronary artery is not frequently encountered¹². We documented double vessel coronary disease which involves two main arteries but did not specify it to left main trunk. Individually left circumflex artery was involved in 0% of the civilians in comparison to 16% of the military personnel. This difference was statistically highly significant ($p=.003$). Left anterior descending coronary artery was the culprit artery in 64% of the civilians in comparison to only 18% of the military personnel ($P = 0.001$). Left anterior descending coronary artery was the major culprit in acute myocardial infarction as a whole causing 41% of the total cases in both the sectors combined. Right coronary artery was involved in 8% of the civilians and 4% in military sectors with no significance ($p=.400$). It caused minimum myocardial infarction in both the sectors. On the other hand acute myocardial infarction in young military patients may have some characteristics that are different from those in older patients and these vary in different sectors of the society¹³. We observed multiple arteries involved in 45% of patients.

Double vessel coronary artery disease was present in 2% in civilian population in comparison to 20% in military setup. This difference was statistically significant ($p=.004$). There are few reports demonstrating multiple arterial involvements, especially among the young people with acute myocardial infarction¹⁴. According to AFMS Haque, AR Siddiqui, SMM Rahman, et al 26.56% patients had DVCAD and TVCAD was present among 20.31 % patients¹⁵. According to another author triple vessel coronary artery disease prevailed in 22.6% of the patients with acute myocardial infarction¹⁶. We observed Triple vessel involvement in 42% of the military person in comparison to 26% in civilians and 34 % in the both sectors combined, being the second commonest coronary artery disease as a whole. This difference was not statistically significant ($p>0.05$). Compared with civilian population military persons,

for their service promotion might be reluctant to seek medical intervention at an early stage of disease. Civilians having no such promotion issues pertaining to health are bound to seek medical intervention as early as possible. We could not find any other reason contributing to predominant involvement of multiple vessels among the military hospital patients.

CONCLUSION

Coronary arteries involvement varies in different sectors of the society. Military persons suffer from multiple coronary artery involvement in their first myocardial infarction (TVCAD and DVCAD) without any reason. Left anterior descending coronary artery is main culprit in civilian population suffering from acute myocardial infarction and as whole in the community. Left circumflex coronary artery is involved only in the military personnel. Right coronary artery, individually, causes minimum cases of acute myocardial infarction.

REFERENCES

1. Birnbaum Y, Solodky A, Herz I, et al. Implications of inferior ST-segment depression in acute anterior myocardial infarction: electrocardiographic and angiographic correlation. *Am Heart J* 1994; 127:1467-73.
2. Gupta A, Lokhandwala YY, Kerkar PG, et al. Electrocardiographic differentiation between right coronary and left circumflex coronary arterial occlusion in isolated inferior wall myocardial infarction. *Indian Heart J* 1999; 51:281-284.
3. Mehta SR, Eikelboom JW, Natarajan MK, et al. Impact of right ventricular involvement on mortality and morbidity in patients with inferior myocardial infarction. *J Am Coll Cardiol* 2001; 37:37-43.
4. Shamir R, Mehta, John W.Eikelboom, et al. Impact of Right Ventricular Involvement on Mortality and Morbidity in Patients With Inferior Myocardial Infarction. *J Am Coll Cardiol* 2001; 37: 37-43.
5. Zehender M, Kasper W, Kauder E, et al. Right ventricular infarction as an independent predictor of prognosis after acute inferior myocardial infarction. *N Engl J Med* 1993; 328:981- 8.
6. Yamaji H, Iwasaki K, Kusachi S, et al. Prediction of acute left main coronary artery obstruction by 12-lead electrocardiography: ST segment elevation in lead aVR with less ST segment

-
- elevation in lead V1. *J Am Coll Cardiol.* 2001; 38: 1348-1354.
7. Yoshitomi Y, Kojimam S, Uramcchi M. Acute myocardial infarction with simultaneous occlusions of two major coronary arteries in a young man. *Clin Cardiol* 1998; 21:140-142.
 8. Burke A, Virmani. Significance of multiple coronary artery thrombi: a consequence of diffuse atherosclerotic disease. *Ital Heart J* 2000; 12:832-4.
 9. Goldstein J A, Demetriou D, Grines C L, et al. Multiple complex coronary plaques in patients with acute myocardial infarction. *NEng J Med* 2000; 343: 915-22.
 10. Garbo R, Steffino G, Dellavalle A, et al. Myocardial infarction with acute thrombosis in multiple major coronary vessels. *Ital Heart J* 2000; 12: 824-31.
 11. Nakagawa T, Yasuno M, Tauahashi H, et al. A case of acute myocardial infarction intra coronary thrombosis in two major coronary arteries due to hormone therapy. *Angiology* 1994; 45: 333-338.
 12. De Feyter PJ, Serruys PW. Thrombolysis of acute total occlusion of the left main coronary artery in evolving myocardial infarction. *Am J Cardiol* 1984; 53:1727-8.
 13. Uhl G, Colinet L, Farrel P W, Colinet L. Myocardial infarction in young adults. Risk factors and natural history. *Am Heart J* 1983; 105: 548-553.
 14. Zimmerman F, Cameron A, Fisher L D. Myocardial infarction in young adults. Angiographic characterization, risk factors and prognosis (coronary artery surgery study registry). *J Am Cardiol* 1995; 26:654-661.
 15. Haque AFMS, Siddiqui AR, Rahman SMM, et al. Acute Coronary Syndrome in the Young – Risk Factors and Angiographic Pattern. *Cardiovasc. J.* 2010; 2: 175-178.
 16. Chikamori T, Doi Y, Yonezawa Y, et al. Noninvasive identification of left main and triple vessel coronary artery disease using dipyridamole thallium scintigraphy. *J Cardiol* 1993; 23:141-7.

AUTHORS

- **Prof. Dr. Muhammad Ashraf Chaudhry**
Professor of Community Medicine
CMH Lahore Medical College, Lahore
- **Dr. Hamza Malik**
CMH Lahore Medical College, Lahore
- **Dr. Mujadad Ahmed Khan Niazi**
CMH Lahore Medical College, Lahore
- **Dr. Saeed Arif**
CMH Lahore Medical College, Lahore
- **Dr. Saqib Kirwan Walayat**
CMH Lahore Medical College, Lahore

Address of Correspondence

Prof. Dr. Muhammad Ashraf Chaudhry
Head of Department of Community Medicine
CMH Lahore Medical College, Lahore
Email: drmachaudhry@gmail.com

EDITORIAL COMMENTS

It is an interesting study done by preventive physicians. It is a good effort. However following observation have been made.

1. Lesion of LAD were found to be more common in civilians as compared to military personnel. LAD lesion are known to be associated with more severe disease.
2. TVCAD was found to be more common in military personnel indicating more severe disease in military personnel.
3. Lt. CX artery was found to be involved in military personnel only but no civilians but when describing TVCAD there were 26% civilians & 42% military personnel. This needs further clarification or correction which may be cardiology involved in Cardiology.

Dr. Aamir Hussain

Associate Professor of Medicine
PMC/ Allied Hospital, Faisalabad