

# Vesicovaginal Fistula: Repair by Vaginal Approach

Sanauallah, Lubna Aslam, Mumtaz Ahmed

---

## ABSTRACT

**Objectives:** To evaluate the outcome of trans-vaginal repair in vesicovaginal fistula even in cases having fistulous opening high in vagina or close to ureteric orifices.

**Methods:** This study was carried out in Departments of Urology and Gynecology Lahore General Hospital from April 2004 to Oct 2007. Detailed history was taken; physical examination and relevant investigations were carried out. In extended lithotomy position, simultaneous cystoscopy and vaginal examination were performed in all cases. After identifying the fistula and ureteric orifices, trans-vaginal repair was done in all the cases.

**Results:** Thirty cases of urinary incontinence for 3 months to 12 years, with age range of 18 to 49 years and their parity ranged from 1 to 6. Sixty six

percent fistulas were supra-trigonal and less than 2 cm (range 1-4cm). It was seen that obstetrical causes (59.4%) overruled the gynecological ones (33.3%). Five patients had one or more previous fistula repair attempts; while one of the females had 4 deliveries even with the fistula. First repair attempt was successful in 27 (91.1%) cases, two of the remaining three were cured in 2<sup>nd</sup> repair and last one was cured in third trans-vaginal attempt. None of the repair compromised the ureteric orifice.

**Conclusion:** The vaginal approach avoids laparotomy, splitting of the bladder and ureter re-implantation in the cases having fistulae closed to the ureteric orifice. Patient recovery is faster with less morbidity.

**Keywords:** Urinary leakage, Vaginal approach, VVF repair.

---

## INTRODUCTION

Vesicovaginal fistula (VVF) is an abnormal fistulous tract extending between the bladder and the vagina as a result of ischemic necrosis of the vaginal wall of vault and posterior bladder wall. In addition to the medical sequel, they often have a profound effect on the patient's emotional well-being and social life. The fistulae usually result from complications of child birth, and pelvic diseases and their treatment. In developed countries, the most common cause of VVF is iatrogenic injury during gynaecological surgery[5-6]. In developing countries like ours, in addition to gynecological injuries; obstetrical causes are the leading ones of vesicovaginal fistulae (VVF)[8]. The best chance for success is by the surgeon who has expertise of VVF repair for that appropriate route. The literature documents excellent success rates for both the vaginal and abdominal approaches. Minimal blood loss, shorter operative time, faster recovery and low postoperative morbidity are hallmarks of the vaginal approach, making it an attractive option. Additionally, this approach obviates bowel manipulation, reducing

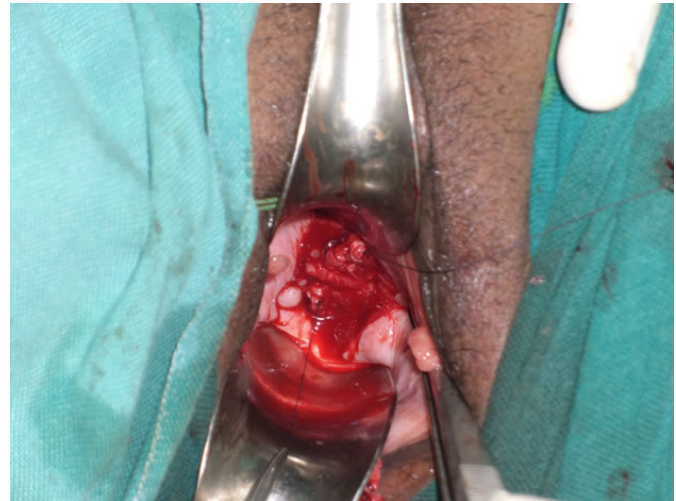
operative morbidity, particularly in patients with repeated pelvic surgeries and recurrent VVF. The purpose of the study was to evaluate the outcome of the surgical technique of trans-vaginal repair even in cases having fistula close to ureteric orifices or high in vagina.

## MATERIALS AND METHODS

This study was carried out in Department of Urology in collaboration with Gynecology Department, Lahore General Hospital, Lahore from Apr 2004 to Mar 2007. Detailed history was taken to record age, nature of trauma, duration of urinary leakage and previous attempts of repair if any. Thorough physical examination, hemoglobin estimation, serum creatinine, blood sugar level, ECG and X-ray chest if required were carried out. Ultrasonography and contrast studies were done to document the fistula. The principles of VVF repair followed were adequate preoperative nutritional repletion, well-vascularized healthy tissue for repair, adequate exposure of the fistula tract, good

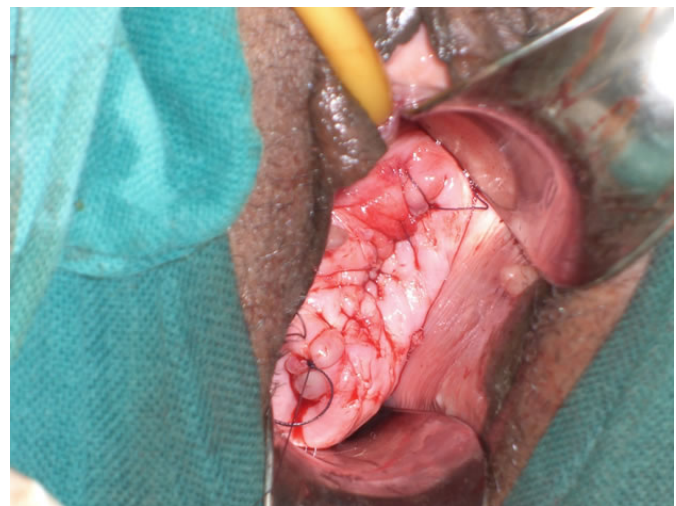
hemostasis, judicious use of cautery, watertight closure of each layer, multiple layer closure, tension-free non-overlapping suture lines, adequate urinary drainage after repair and prevention of infection (use of pre, post and intraoperative antibiotics). Simultaneous cystourethroscopy and vaginal examination under anesthesia was performed to confirm and localize the VVF, identify the ureteric orifices and assess the vaginal tissue mobility and its length. Trans-vaginal repair was done in all cases where the ureteric orifices were identified; even the fistula was lying close to the orifices. Ureteric catheters were necessary during repair in the cases where ureteric orifices were at risk. Exclusion criteria for vaginal repair were failure to identify ureters on cystoscopy, fistula involving the ureters or the patient's preference for an abdominal approach during preoperative counseling. With the patient in lithotomy position, the balloon of Foley catheter (8-16Fr), inserted through the fistula into the urinary bladder, was inflated for traction to bring the fistulous tract into view and facilitate the dissection. In case of small fistula, the tract was gently dilated to 12F, and 8Fr Foleys catheter was used for traction. Suturing of the labial folds to the ipsilateral thigh provided improved visibility of the vaginal vault. The vaginal wall was incised circumferentially at a distance of 1-1.5cm from the fistula opening and widely dissected from the underlying endopelvic fascia, which is relatively bloodless whitish tough tissue plane. A row of 4-0 polyglycolic acid suture was placed in the raw fascia in a way to incorporate the partial thickness of the bladder wall and invert the margins of the fistula. The circumferential vaginal flap was inverted as a part of bladder layer in patients where ureteric orifices were at risk in repair (Fig 1). The continuous sutures were tied after removal of the catheter from the tract. A second row of interrupted sutures was applied at a distance of 1cm from the first row in order to fully imbricate the first layer. The leakage was ruled out by irrigating the bladder with 200 ml diluted methylene blue through wide bore per-urethral Foley catheter at the end of 2<sup>nd</sup> suture line. Suturing of the vaginal wall was then performed, providing a third layer of closure (Fig 2). In the post operative period, antibiotic was continued and uninterrupted continuous bladder drainage was maintained for 2 weeks. Vitamin C (500 mg orally 3 times per day) to acidify urine, stool softeners to minimize valsalva maneuvers in constipated patient and anti-spasmodic was advised in selected patients.

Pelvic and speculum vaginal examination was avoided during the first four weeks and coitus was prohibited for a minimum of three months. Successful repair was defined as satisfactory voiding with no leakage of urine through vagina and compromise of ureteric orifice at follow up visits.



**Fig. 1: First row of suture line**

The continuous suture is tied after removing the Foley catheter



**Fig. 2: Third row of suture line.**

Vaginal wall is repaired in a way that the suture line is away from the first row line.

## RESULTS

The thirty patients presented with involuntary loss of urine all the time through vagina with no desire to void. Their age, parity and causative factors are shown in table-1. The distribution of the patients

according to site and size of the fistulae is shown in table-2. Duration of urine leakage ranged from 3 months to 12 years; and five out of the 30 patients had one or more repair attempts before presenting in our hospital; while one of the females had 4 deliveries even with the fistula. It was observed that obstetrical causes overruled the gynecological ones; obstructed labor was the causative factor in 14 (46.2%) patients. Out of the abdominal deliveries, three were in rural health center and one in a district hospital. The one fistula following cesarean section occurred in our hospital in a patient referred for obstructed labor. Regardless of the previous vaginal or abdominal repair attempt, all patients were operated trans-vaginally. First repair attempt was successful in 27 (91.1%) cases and two of the three failed cases had history of failed trans-abdominal repair. The only patient who had 2<sup>nd</sup> attempt failure had fistula of >3 cm, whose repair was successful in third trans-vaginal attempt. On follow up visits, investigations proved that none of the repair compromised the ureteric orifice.

**Table-1**  
**Patient Data**

Etiology	Number	Age group (year)	Number	Parity	Number
Obstructed labor	14 (46.2%)	< 20	02 (06.6%)	0	02 (06.6%)
Low segment c/s	04(13.2%)	21-30	16 (52.8%)	1-2	17 (56.1%)
Hysterectomy	10 (33%)	31-40	07 (23.1%)	3-4	05 (16.5%)
Dilatation & curettage	02 06.6%)	≥ 41	05 (16.5%)	5-6	06 (19.8%)

Distribution of patients according to etiology, age and parity (n =30)

**Table-2**  
**Fistula Data**

SITE	n	SIZE	n
Supra trigonal	15 (50%)	<1 cm	08 (26.64%)
Infra trigonal	05 (16.66%)	1-2cm	15 (50%)
close to ureteric orifices	10 (33.33%)	≥ 3cm	07 (23.31%)

Site and size of the fistulas (n = 30)

## DISCUSSION

The anatomical proximity of the urinary and genital systems predisposes the urinary tract to injury after complicated deliveries as well as difficult pelvic surgery. Although gynecological surgery accounts for

the majority of the VVF in developed countries, the scenario is completely different in developing countries where proper intra-natal care is still not available and hence birth related injuries remain the leading cause of vesicovaginal fistula. In the developed countries, most of the obstetric fistulas occurred before 1940[8]. Pakistan is the seventh most populous country of the world with a population over 140 million and majority of the births occur in rural areas usually conducted by traditional birth attendants (TBA's). Abdominal deliveries and hysterectomies by inexperienced hands increase the burden of female urinary incontinence. The high frequency of VVF in our country reflects the low socio-economic status and lack of proper obstetrical and gynecological care.

Raut V and Bhattacharya[7] observed that 75% VVF were related to gynecological surgery and it was noted in 80% of the cases studied by Lee et al[6]; while we observed in 30% of patients. In our study, the fistula arising from delivery related complications was observed in almost 66% of the cases. VVF was birth related in 83.8% and 96.5% of cases in two different studies from Nigeria. The fistula arising out of obstetrical complications was noted in 89.61% of patients studied by Chaudhuri D et al from India and 80% of the cases studied by Raza NK et al from Pakistan [9-12].

With increasing experience, most of the VVFs can be repaired by vaginal route as it is the procedure of choice. In a study by Brian Hancock & Mhairi Collie [13], 252 (84%) of the 298 cases were repaired trans-vaginally. In the study conducted by Chaudhuri D et al [11], 96% of the cases were repaired by vaginal route. Being the less morbid approach, it was preferred by Kumar Santosh et al [14].

Results published from the fistula hospital by Kees Waaldijk and from Ann Ward in southern Nigeria are encouraging; with over 90% healing achieved overall [15-16]. Success rates at primary attempts were 90% & 93.33% respectively in studies by Brian Hancock[13] and Chaudhuri D et al [11]. It was almost 93% in studies carried out by Sinha HH and Sarkar B et al [17-18]. Our results are comparable with these studies.

## CONCLUSION

The vaginal approach avoids laparotomy, splitting of the bladder and ureter reimplantation. Patient recovery is shorter with less morbidity. The procedure can be done as day care surgery; results comparable to those of the abdominal approach.

---

## REFERENCES

1. Jobert de Lamballe AJ. In: Balliere, Fils, eds. *Traite Des Fistules Vesico-Uterines*. Paris, France; 1852.
2. Collis M. Further remarks on a new successful mode of treatment for vesicovaginal fistula. *Dublin QJ* 1861;31: 302-16.
3. Latzko W. Behandlung hochsitzender Blasen und Mastdarmscheiden Fistein nach Uterus Extirpation mit hohem Scheidenschluss. *Zentralbl Gynakol* 1914; 38: 906.
4. Latzko W. Postoperative vesicovaginal fistulas: genesis and therapy. *Am J Surg* 1942; 58: 211.
5. Goodwin WE, Scordino PT. Vesicovaginal and ureterovaginal fistulae, a summary of 25-years of experience, *J Urol* 1980; 123-367.
6. Lee RA, Symmonds RE, Williams TJ. Current status of genitourinary fistula. *Obstet Gynecol* 1988; 72:313-9.
7. Rant V, Bhattacharya M. Vesical fistulae. An experience for a developing country. *J PGM*;1993:39 20-1.
8. Keettel WC. Vesicovaginal and urethrovaginal fistulas. In: Buchsbaum HJ, Schmidt JD (eds). *Gynecologic and Obstetric Urology*. Philadelphia: WB Saunders. 1978:268.
9. Wall LL, Karshima JA, Kirschner C, Arrowsmith SD. The obstetric vesicovaginal fistula: characteristics of 899 patients from Jos, Nigeria. *Am J Obstet Gynecol* 2004;190:1011-9.
10. Tahzib F. Epidemiological determinants of vesicovaginal fistula. *Br J Obstet Gynaecol* 1983; 90:387-91.
11. Chaudhuri D, Goswami S, Adhikari S, Sanghamita M. Analysis of vesicovaginal fistulas in Eden hospital - a 10 year study. *J Obstet Gynecol India* 2007;57:139-41.
12. Raza MK, Nabeela R, Jehanzaib M, Ruqia S. Vesicovaginal Fistula: An experience of 30 cases at Ayub Teaching Hospital Abbottabad. *JAMC* 2005; 17.
13. Brian Hancock & Mhairi Collie. Vesico-vaginal fistula surgery in Uganda. *East and Central African Journal of Surgery* 2004; 9:32-7.
14. Kumar S, Kekre NS, Gopalakrishnan G. Vesicovaginal fistula: An update. *Indian J Urol* 2007; 23:187-191.
15. Hilton P and Ward A. A review of 25 years experience in South East Nigeria. *Int.Urogynaecology* 1998;9:189-94.
16. Waaldijk K. Surgical classification of obstetric fistulas. *Int J Gynaecol Obstetric*1995; 49:161-3.
17. Sinha HH, Mishra M. A review of urinary fistulae. *J Obstet Gynecol India* 2000; 50:79-80.
18. Sarkar B, Ghosh RS, Saha SK et al. A study of genitourinary fistulae in North Bengal. *J Obstet Gynecol India* 2001; 51:165-9.

## AUTHORS

- **Dr. Sanaullah**  
Senior Registrar Urology  
Lahore General Hospital Lahore.
- **Dr. Lubna Aslam**  
Senior Registrar Gynae Unit 1, LGH  
Lahore General Hospital, Lahore
- **Dr. Mumtaz Ahmed**  
Associate Professor (Urology)  
Post Graduate Medical Institute (PGMI) /LGH.  
Lahore.