

# Hypospadias Repair; Seven years experience at Allied Hospital Faisalabad

Muhammad Akmal, Safdar Hassan Javed, Ghulam Mahboob Subhani, Ashraf Ali Jafari, Naveed Ashraf,  
Muhammad Hussain, Zahid Iqbal

---

## ABSTRACT

**Objectives:** To compare the results of Tubularized Incised Plate Urethroplasty with Mathieu repair and transverse inner periputial skin flap (Asopa's repair).

**Methodology:** For Distal Hypospadias repair 30 patients were treated with Tubularized Incised Plate Urethroplasty and 30 were managed with Mathieu repair. For proximal hypospadias repair 20 patients were treated by Tubularized Incised Plate Urethroplasty and 20 patients were managed by Asopa's repair.

**Results:** The mean age at presentation was 7 years. Good cosmetic and functional results were achieved by all techniques. The overall success rate of Tubularized Incised Plate Urethroplasty was 86.6% and that of Mathieu repair 83.3% for the management of distal hypospadias. Success rate of Tubularized Incised Plate Urethroplasty was 85% and that of Asopas repair was 75% for the management of proximal hypospadias. Regarding

Distal Hypospadias. In Mathieu repair; Urethrocutaneous fistula developed in 04 patients and total disruption in 01 patient. Meatal stenosis occurred in 02 cases who responded well to regular dilatation. In Tubularized Incised Plate urethroplasty 03 patients developed urethrocutaneous fistula. Total disruption in 01 patient and meatal stenosis was seen in 03 cases which responded well to regular dilatation. Regarding proximal Hypospadias. In Tubularized incised plate Urethroplasty; 03 patients developed urethrocutaneous fistula and 01 patient presented with total disruption. Meatal stenosis was seen in 01 patient that needed meatotomy. In Asopas repair 03 patients developed urethrocutaneous fistula and 02 presented with total disruption.

**Conclusion:** All the techniques are good for hypospadias repair. However Tubularized incised plate Urethroplasty proved to be the better technique for management of all type of hypospadias.

**Key Words:** Hypospadias, Urethroplasty, Complications.

---

## INTRODUCTION

The term hypospadias is derived from the Greek word 'hypos' meaning "under" and 'spadon' meaning "rent" or "fissure." [1]. It is one of the most common genital anomalies which affect approximately 8.2 per 1000 live male births. [2] In this condition the urethral meatus is situated on the ventral surface of the penis, from just below the tip of the glans to the perineum in the most severe cases. [3] The most accepted classification of hypospadias is according to the meatal location after chordee correction. It is anterior in 65-70%, middle in 10-15% and posterior in 20% of the cases [4]. The traditional goals of hypospadias surgery have been focused on the

functional aspects of the repair, which are a straight penis with a glanular meatus to permit voiding while standing, and to allow effective coitus in adulthood. [5] A number of procedures like MAGPI [6], Mustarde [7], Mathieu [8], Horton-Denine flip-flap procedure [9], Snodgrass tubularized incised plate urethroplasty technique [10] have been described to repair the anterior hypospadias. Similarly multiple options like Theirsch Duply repair, Tubularized incised plate urethroplasty [11], Asopas repair. Different graft techniques are available (the most common type), suggesting that none is ideal. Urethral fistula still remains a common and the significant cause of

morbidity.[12,13] In general, there is a lack of objective assessment of the cosmetic results of hypospadias repair by independent health professionals who have not been involved in the patients care. Oswald J compared Mathieu repair with Tubularized incised plate urethroplasty[14]. Our aim was to evaluate whether Tubularized incised plate urethroplasty has better cosmetic results than two other established techniques.

### PATIENTS AND METHODS

This study was carried out in Department of Urology Allied Hospital, Faisalabad from May 2001 to April 2007. 100 patients were included in the study. Diagnosis was made on clinical basis. All patients were operated by a team of surgeons.

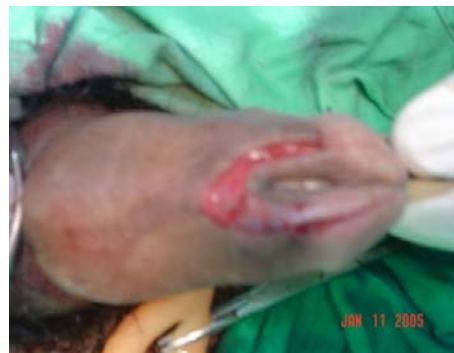#### Inclusion Criteria:

- Patient operated for the first time.
- Uncircumcised patients.
- Patients with minimal chordee.

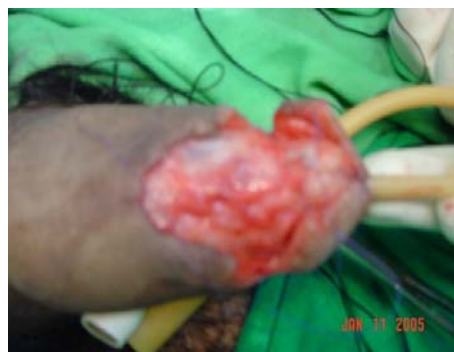#### Exclusion Criteria:

- Multiple failures.
- Circumcised patients.
- Severe chordee.

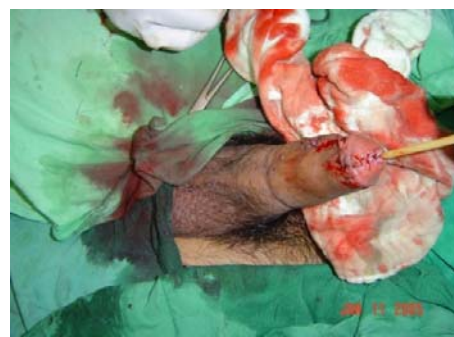**Procedure:** In Tubularized Incised Plate Urethroplasty stay suture was placed in the glans tip. Two parallel incisions were made from the glans tip to just proximal to the urethral meatus. Incision was made approximately at the width of 7 to 9 mm according to the phallus size. Two parallel incisions were joined at about 2 mm proximal to the urethral meatus. Circumferential incision was made for penile degloving. A longitudinal midline incision of the urethral plate was made from the glans tip to the urethral meatus. The urethral plate was tubularized over a stent. Wide meatus was fashioned. Subcutaneous tissue cover on neourethra was made. Glans wings were approximated under minimal tension in two layers. Skin cover was made by Blair Byar's technique[14].



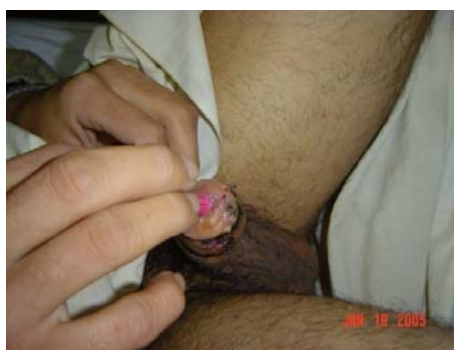**Fig-A-1**



**Fig-B-1**



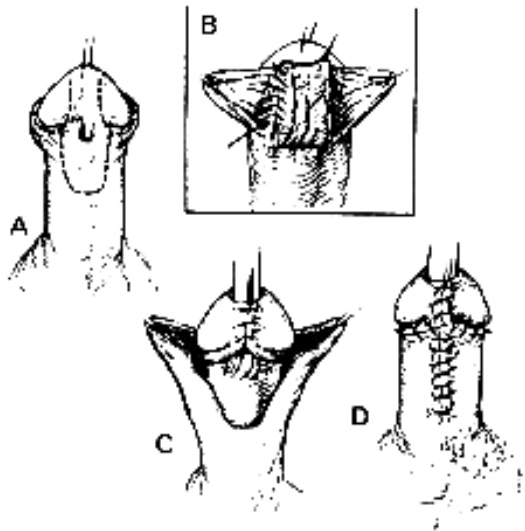
**Fig-C-1**



**Fig-D-1**

**Fig.1.A-D: Tubularized Incised Plate Urethroplasty**

In Mathieu repair two parallel incisions were made proximal to meatus at about 5 to 8 mm width. Reverse flap was taken from the penile skin according to the required tube to be formed. Incisions were extended up to the glans tip in distal direction. Circumferential subcoronal incision was made for penile degloving. Reverse flap Urethroplasty was done. Glans wings were raised. Urethral tube was buried under glans wings and Glanuloplasty was done in two layers. Skin cover was made by Blair-Byar's technique.

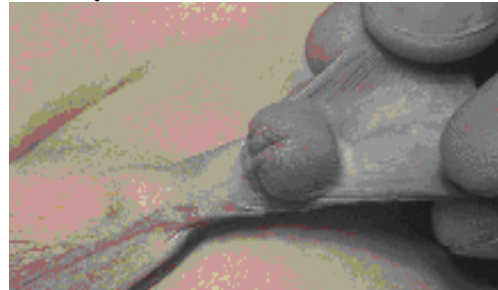


**Fig. 2. A-D: Mathieu Repair**

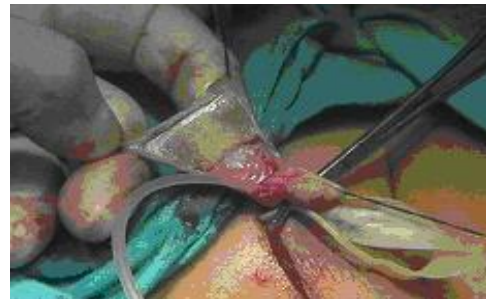
In Asopas Repair after chordee correction prepuce was arranged as rectangle placed transversely. Size was measured according to size of the urethral gap. Skin of the prepuce was incised while keeping blood supply intact. Neourethral tube was formed on a stent. The outer prepuce skin was cut on both sides obliquely leaving the central part of the skin intact. The glans tunnel was created with scissors and flap was rotated to the right side. The end of the neourethra was anastomosed to the spatulated native urethra and distal end was brought through the glans channel and anastomosed to the opening in the glans. The outer preputial skin covers the ventral penis. Lt sided scrotal incision was made sometime if required then Z-Plasty at the penoscrotal junction was done.

All patients were operated by a team of surgeons. Hypospadias was repaired with PDS (polydioxanone) 7/0. All operation details relating the site of Hypospadias, cause of Chordee and type of repair were recorded. All the cases were followed for 3 months.

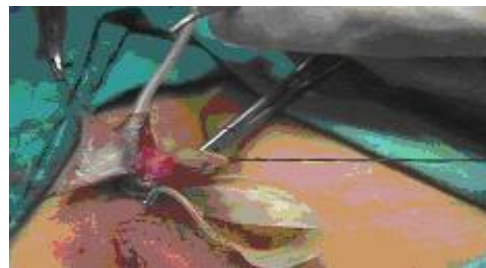
Mathieu repair was compared with Tubularized incised plate urethroplasty for the management of distal hypospadias. Asopas repair was compared with Tubularized incised plate urethroplasty for the treatment of proximal hypospadias. Data was analysed statistically by chi-square. For Distal Hypospadias  $\chi^2$ -value = 0.131, p-value=0.718 and for Proximal Hypospadias  $\chi^2$ -value= 0.625, p-value = 0.429, no significant difference between two techniques was reported at any level.



**Fig-A-3**



**Fig-B-3**



**Fig-C-3**



**Fig-D-3**

**Fig. 3. A-D: Asopa repair**

## RESULTS

A total of 100 random patients were included in the study. They were operated in Allied Hospital, Faisalabad from May 2001 to April 2007. Age range from 02 years to 30 years with mean age of 7 years. As shown in table I distal hypospadias was present in 60 (60%) cases. 40 (40%) patients presented with proximal hypospadias. Table-I. Associated anomalies were found in 10 (10%) patients. Including unilateral undescended testes in 04 (4%) cases, bilateral undescended testes in 2 (2%) patients and hernia in 4 (4%) patients.

**Table-1**  
**Types of Hypospadias**

Sr. #	Hypospadias	No.	%
1	Distal Hypospadias	60	60%
2	Proximal Hypospadias	40	40%

Regarding distal hypospadias, 30 patients were operated by Mathieu repair in which 04 (13.2%) patients developed urethrocutaneous fistula and 01 (3.3%) case presented with total disruption. 02 (6.6%) patients developed meatal stenosis which was managed by regular dilatation. In Tubularized incised plate urethroplasty. 03 (9.9%) patients developed urethrocutaneous fistula and 01 (3.3%) patient developed total disruption. Meatal stenosis was seen in 03 (9.9%) cases, who responded well to regular dilatation as seen in Table-II, III.

**Table-2:**  
**Types of Hypospadias Repair**

Procedure	Distal Hypospadias	Proximal Hypospadias
Mathieu Repair	30	Nil
Tubularized Incised Plate Urethroplasty	30	20
Asopa's Repair	Nil	20

**Table-3**  
**Complications of Distal Hypospadias Repair**

Complications	Mathieu Repair	Tubularized incised plate urethroplasty
Infection	01 (3.3%)	01 (3.3%)
Haematoma	02 (6.6%)	03 (6.6%)
Fistula	04 (13.2%)	03 (13.2%)
Total Disruption	01 (3.3%)	01 (3.3%)
Meatal Stenosis	02 (6.6%)	03 (9.9%)

Regarding proximal hypospadias 20 cases were operated by Asopa's repair. 03 (15%) patients

developed urethrocutaneous fistula and 02 (10%) presented with total disruption. 20 cases were operated by Tubularized incised plate urethroplasty and 03 (15%) of them developed urethrocutaneous fistula and 01 (5%) patient presented with total disruption. 01 patient developed meatal stenosis who required meatotomy as presented in Table-IV.

**Table-4**  
**Complication of Proximal Hypospadias Repair**

Complications	Tubularized Incised plate Urethroplasty	Asopas Repair
Infection	02 (10%)	03(15%)
Haematoma	01 (5%)	02 (10%)
Fistula	03 (15%)	03 (15%)
Total Disruption	01 (5%)	02 (10%)
Meatal Stenosis	01 (5%)	Nil

Overall success rate of Mathieu repair was 83.3% and Tubularized incised plate urethroplasty was 86.6% for the management of distal hypospadias (Table-V).

**Table-5**  
**Overall Results of Distal Hypospadias Repair**

Type of Repair	Success	Failure
Mathieu Repair	25 (83.3%)	05 (16.7%)
Tubularized Incised Plate Urethroplasty	26 (86.6%)	04 (13.4%)

Overall success rate of Asopa's repair was 75 % and Tubularized incised plate urethroplasty was 85% for the management of proximal hypospadias (Table-VI).

**Table-6**  
**Overall results of Proximal Hypospadias repair**

Type of Repair	Success	Failure
Tubularized Incised Plate Urethroplasty	17 (85%)	03 (15%)
Asopa's Repair	15 (75%)	05 (25%)

## DISCUSSION

A total of 100 patients were included in this study. Their age ranged from 2-30 years with mean age of 07 years. Muhammad Riaz Ul Haq et al conducted study and age of the patients ranged from 1-14 years[15]. Sixty (60%) cases presented with distal hypospadias and 40 (40%) with proximal hypospadias. Maqbool et al noted similar findings[16]. Associated chordee was present in 50% of cases of proximal

---

hypospadias. Maqbool et al found chordee in 68.4% of cases[16].

Artificial erection was done with 0.9% normal saline at the beginning of procedure. It is in accordance with most of the series[17]. Kogan has reported good results with aloprostadil administered intracavernously than normal saline[18]. Chordee was corrected by dorsal tunica albugenia plication if needed.

There is no single treatment option for distal Hypospadias repair. Immediate local skin for repair of Hypospadias is 1st choice as in Tubularized incised plate Urethroplasty and Thiersch Duplay repair. Meatal based skin can also be used for Urethroplasty as in Mathieu repair & Barkat procedure. MAGPI can be used for glanular Hypospadias repair[19].

For distal hypospadias repair we treated 30 (50%) patients with Tubularized incised plate Urethroplasty. Single stage repair was done in all cases. Overall complications rate was 13.4% for Tubularized incised plate Urethroplasty.

Holland and Smith[20] repaired distal Hypospadias with Tubularized incised plate urethroplasty with complication rate of 22 %. Similar Tubularized incised plate urethroplasty was done by lane S. Palmer et al [21] with success rate of 90 %. Shanberg AM, et al[22] performed reoperative Tubularized incised plate urethroplasty in 13 patients and faced 14 % complications. Earl Y Cheng et al [23] performed Tubularized incised plate urethroplasty for distal and proximal hypospadias and obtained 99 % success.

Thirty (50%) patients were treated with Mathieu repair. Overall complications rate was 16.7% Muhammad Riaz ul Haq et al[15] performed modified Mathieu repair. Complications rate was 22.9 %. Hayashi Y et al[24] have shown 19 % complication rate in their 16 patients treated with this method. Samuel M, et al repaired distal hypospadias by Mathieu repair and observed 1.5 % reoperation in their series [25].

Koltuksuz U et al[26] obtained 100 % success by repairing distal hypospadias with Mathieu technique.

Forty cases of proximal hypospadias were included in this study. TIP urethroplasty was done in 20 cases. Overall complications rate was 15%.

TIP urethroplasty can be successfully used in the more severe, proximal forms of hypospadias[27,30,31]. The modified TIP procedure is a safe and reliable technique. It provides excellent cosmesis with a low reoperation rate[28]. Healing of

the incision in the dorsal urethral plate during Tubularized incised plate urethroplasty occurs by re-epithelialization with normal tissue ingrowth. In contrast, the sutured closure heals with a desmoplastic and inflammatory response[29,32].

Oswald et al compared Mathieu repair with incised plate urethroplasty and they found Tubularized incised plate urethroplasty the preferred technique with only 3 % complications rate[14]. Use of inner preputial skin is an alternative option. Grafts may be used for Urethroplasty of any type.

Twenty cases were repaired by Asopa's technique and reliable results were achieved. It has been reported that Asopa procedure reliably achieves the goals of hypospadias repair: release of chordee, urethroplasty, scrotoplasty and redistribution of skin coverage in one operation[30] Asopa procedure provides excellent results for the patients of hypospadias and chordee [33]. Fistula formation is the main complication of this technique[34].

Urethrocutaneous fistula was main complication of all types of procedures.

Proper antiseptic cotton gauze dressing was done in every case and was kept for 24 hours. It is similar to the protocol of Maqbool A et al[16] and Muhammad Riaz ul Haq et al[15]. Van Savage JG et al compared dressing versus no dressing for hypospadias repair and concluded that results are independent of dressing usage.

We used (PDS) Polydioxone 7/0 suture for hypospadias repair. Tube was formed by continuous stitching. Dorsal slit was made in the midline on preputial & dorsal penile skin if necessary. Dorsal skin was brought to ventral side by Byar's flap. Skin closure was done with vicryl No 4/0. Post operative antibiotics were used for 10 to 12 days.

Tubularized incised plate Urethroplasty showed adequate results to treat both distal & proximal Hypospadias. Second layer of dartos fascia reduced the rate of fistula formation.

## CONCLUSION

All techniques mentioned in study can be applied safely to repair hypospadias. TIP urethroplasty proved the better possible method to treat all types of hypospadias but with its limitation to intact urethral plate. Complications can be minimized by applying second layer of dartos fascia or tunica vaginalis, improving surgical skill, avoidance of haematoma formation and prevention of infection.

## REFERENCES

1. Zaontz MR, Packer MG. Abnormalities of external genitalia. *Pediatr Clin North Am* 1997; 44: 1267-97.
2. Sweet RA, Schrott HG, Kurland R, Culp OS. Study of the incidence of hypospadias in Rochester, Minnesota 1940-1970 and a case control comparison of possible etiologic factors. *Mayo Clin Proc* 1974; 49: 52-8.
3. Winslow BH, Devine CJ Jr. Principles in the repair of hypospadias. *Semin Pediatr Surg* 1996; 5: 41-8.
4. Barcat J. Current concepts of treatment. In: Horton CE, (edi). *Plastic and reconstructive surgery of genital area*. Boston: Little Brounand, 1973: 249-63.
5. Baskin LS, Duckett JW. Hypospadias. In Stringer MD, Oldham KT, Mouriquand PDE, Howard ER eds, *Pediatric Surgery and Urology: Long Term Outcomes*. Chapt 45. Philadelphia: WB Saunders Co, 1998: 559-67.
6. Duckett JW. MAGPI (meatoplasty and glanuloplasty): a procedure of sub coronal hypospadias. *Urol Clin North Am* 1981; 8: 513-9.
7. Mustarde JC. One-stage correction of distal hypospadias. *Br J Plast Surg* 1965; 18:413-22.
8. Mathieu P. Treatment en un temps de l' hypospadias balanique ou juxtabalanique. *J Chir* 1932; 39: 481.
9. Denine CJ, Horton CE. Hypospadias repair. *J Urol* 1977; 18: 188-93.
10. Snodgrass W. Tubularized, incised plate urethroplasty for distal hypospadias. *J Urol* 1994; 151: 464-5.
11. Anwar-ul-Haq, Bader I, Akhter N, Abbasi Z. Tubularized incised plate urethroplasty of hypospadias. *JCPSP* 2004; 14: 489-491.
12. Horton CE Jr, Horton CE. Complications of hypospadias surgery. *Clin Plast Surg* 1988; 15: 371-9.
13. Goepel M, Otto T, Kropft D, Rubben H. Recent consideration for hypospadias repair: results of 252 operations from 1985 to 1990. *Eur Urol* 1996; 29: 63-6.
14. Oswald J, Korner I, Riccabona M Br. Comparison of perimeatal based flap (Mathieu) and the tubularized incised plate urethroplasty (snodgrass) in primary distal hypospadias. *J urol Int*. 2000; 85: 725 – 7.
15. M. Riaz ul Haq, Sarfraz A, M. Afzal, Mazhar Rafi, Nabila Talat, Muhammad Afzal Sheikh. Single Stage Repair of Anterior Penile Hypospadias. *J Surgery Pak Int* 2002; 7: 15-7.
16. Maqbool A, Ahmad H, Waqar A, Anwar S. Two-stage hypospadias repair a method applicable to all types of hypospadias. *JCPSP* 2003; 4: 226 – 228.
17. Vendersteem DR, Husmann DA. Late onset of recurrent penile chordee after successful correction at Hypospadias repair. *J Urol* 1998; 160:1131-3.
18. Baker LA; Mathews RI; Docimo SG. Radial bulbar dissection to correct severe chordee and proximal hypospadias. *J Urol* 2000; 164:1347-9.
19. Uday S, Chatterjee, Manas K, Mandal, Supriyo Basu et al. Comparative study of dartos fascia and tunica vaginalis pedicle wrap for the tabularized incised plate in primary Hypospadias repair. *BJU Int* 2004; 94: 1102-1104.
20. Lane S. Jeffreys. Israel F, Steven CF, Mark EK. Bhagwant G Selwyn BL. The “Long Snodgrass“. Applying the tubularized incised plate to penoscrotal hypospadias in 1 - stage or 2 - stage repairs. *J urol* 2002; 168: 1748 - 50.
21. Earl YC, Sreenivas NV Bradley PK, John CP et al. Snodgrass hypospadias repair with vascularized dortras flap the perfect repair for virgin cases of hypospadias. *J urol* 2002; 168: 1723 – 6.
22. Holland AJ, Smith GHH. Effect of the depth and width of the urethral plate on tubularized incised plate urethroplasty. *J urol* 2000; 64: 489.
23. Shanberg AM, Sanderson K, Duel B. Re-operative Hypospadias repair using the Snodgrass incised plate urethroplasty. *Br J Urol Int* 2001; 87: 544-7.
24. Hayashi Y, Sasaki S, Kojima Y et al. Primary and salvage urethroplasty using Mathieu meatal based flip flap technique for distal hypospadias. *Int. J urol* 2001; 8: 10 – 16.
25. Samuel M, Capps S, Worthy A. Distal Hypospadias: which repair. *BJU Int* 2002; 88-91.
26. Koltuksuz, U. Gursoy, MH. Aydinc, M. Mutus, M.Cetin, S. Karaman, A. An alternative way to cover ventral penile skin defect in Mathieu Technique. *Eur J pediatr surg* 2000; 4:232 – 4.
27. Bar Yosef Y, Binyamini J, Mullerad M, Matzkin H et al. Megameatus intact prepuce hypospadias variant: application of tubularized incised plate urethroplasty. *Urology*. 2005; 66: 861-4.
28. Baccala AA, Ross J, Detore N, Kay R. Modified tubularized incised plate urethroplasty procedure for hypospadias repair. *Urology*. 2005; 66: 1305-6.

- 
29. Bleustein CB, Esposito MP, Soslow RA, Felsen D, et al. Mechanism of healing following the Snodgrass repair. J Urol. 2001;165: 277-9.
  30. Baran CN, Surg N, Kilinc H, Ozdemir R, Sensoz OT. incision technique in distal hypospadias a modification of meatal advancement and glanuloplasty. Plast Reconstr surg.2002; 109: 1018 – 24.
  31. Elicevik M, Tireli G, Demirali O, Unal M, Sander S. Tubularized incised plate urethroplasty for hypospadias reoperations in 100 patients. Int Urol Nephrol. 2007; 39: 823-7.
  32. Braga LH, Pippi Salle JL, Lorenzo AJ, Skeldon S, Dave S, Farhat WA et al. Comparative analysis of tabularized incised plate versus onlay island flap urethroplasty for penoscrotal hypospadias. J Urol.2007; 178: 1451-6.
  33. Wacksman J. Use of the Hodgson xx (Modified Asopa) Procedure to correct hypospadias with chordee: surgical technique and results. J urol. 1986: 136; 1264 – 5.
  34. Frey P; Bianchi A One stage preputial pedicle flap repair for hypospadias: experience with 100 patients. Prog pediater surg. 1989: 23: 181-91.

## AUTHORS

- **Dr. Muhammad Akmal**  
Senior Registrar (Urology)  
Allied Hospital, Faisalabad.
- **Dr. Safdar Hassan Javed**  
Associate Professor (Urology)  
PMC/Allied Hospital, Faisalabad.
- **Dr. Ghulam Mahboob Subhani**  
Assistant Professor (Urology)  
PMC/Allied Hospital, Faisalabad.
- **Dr. Ashraf Ali Jafari**  
APMO (Urology)  
Allied Hospital, Faisalabad.
- **Dr. Naveed Ashraf**  
APMO (Urology)  
Allied Hospital, Faisalabad.
- **Dr. Muhammad Hussain**  
Medical Officer Urology  
Allied Hospital, Faisalabad.
- **Dr. Zahid Iqbal**  
Professor & Head Department of  
Urology and Renal Transplantation  
PMC/Allied Hospital, Faisalabad

