

Giant Vaginal Phlebolith – Lesson Forgotten

Javed Arshad*, S Sultana*, F Mahmood*.

Mrs. R, 54-year-old housewife, presented to A&E, with a history of gross vaginal bleed since the last 12 days. She gave history of complete urinary incontinence since the last 8 years and intermittent vaginal spotting since the past few years.

Her past medical history did not show any systemic illness. Her gynecological history revealed that she was grand multipara (G9P8A1). All the deliveries were vaginal and conducted at home. An obstructed labour resulting in stillbirth complicated her last delivery.

On examination, Mrs. R was middle-aged lady having poor socio-economic background. She was afebrile and normotensive. She was tachycardiac with pulse rate of 104/min. Abdominal examination revealed deep tenderness in the suprapubic region. A deep seated hard mass could be felt in the pelvis. Her other abdominal viscera were not palpable.

Her vaginal examination revealed maceration and excoriation of the vulva and medial side of thighs due to persistent leakage of urine which was foul smelling and haemorrhagic at the time of presentation. Inspection of the vagina showed big occlusive calcareous mass just within the vaginal outlet. Digital rectal examination confirmed presence of big stony hard mass in the vagina, the upper limit of which could not be reached from below. It was mobile on bimanual examination.

Laboratory examination revealed Hb. of 8.3gms/dl, and white cell count of 8600/ml. Her Urea and electrolytes were within normal limits. X-Ray of the pelvis showed a big inverted conical opacity in the pelvis. Her Ultrasound scan did not show any hydronephrosis or any other abnormality in the remaining abdominal viscera, however the pelvis could not be examined as the bladder was empty due to continuous leakage of urine.

On detailed questioning it was learnt that her symptoms dated back to 8 years when she experienced obstructed labour resulting in stillbirth and development of vesico-vaginal fistula (VVF). She was

advised surgery for the same after an interval of three months during which period she was managed conservatively.

First attempt to repair the fistula was made through vaginal route. It was an unsuccessful attempt resulting into persistent leakage of urine. After lapse of another three months, second attempt to repair the fistula through the vaginal route was done but it was also futile. The third attempt was through the abdominal route. The fistula was approached trans-vesically through Pfannenstiel's incision.

For the patient, the result of the third repair was as gloomier as before as she remained incontinent. By then, out of disappointment she decided not to get any future advice and accepted it as her fate. She remained incontinent for 8 years and kept on using improvised pads to control the leakage of urine.

On presentation to us, she was quite reluctant to undergo any further intervention. After a period of counseling and conservative management with antibiotics and blood transfusion, she was taken to theatre for removal of the vaginal stone. Under general anesthetic, examination revealed big, smooth, dirty yellow stone impacted in and filling the entire vagina. An attempt was made to deliver it in toto using lubrication and suprapubic pressure but this attempt was unsuccessful. Later we had to resort to piecemeal removal of the stone after crushing it, which was not difficult. To our surprise, we noted that the cause of stone formation was encrustation over the prolene suture, which was used to repair the fistula as final desperate attempt to control leakage.

The inner side of vaginal mucosa was very unhealthy due to pressure of the stone and associated infection. The posterior wall of the bladder had been totally eroded and both the ureters were opening in the lateral side of the cavity, in the form nipples, formed jointly anteriorly by the anterior bladder wall and posteriorly by the posterior vaginal wall. Owing to the big size of the defect, repair was deferred in favour of future repair, substitution or urinary diversion.

DISCUSSION:

Stone formation in vagina is not unknown. Many cases have been reported in literature. Depending upon the presence or absence of foreign body, these stones may be classified as primary or secondary.

Primary stones are formed in the vagina owing to the deposition of urinary salts as a result of continuous leakage and stasis of urine into the vagina. They have been described in association with urinary leakage caused by vesicovaginal fistulas, urethrovaginal fistulas, an ectopic vaginal ureter, incontinence owing to a neurogenic bladder, meningomyelocele, vaginal outlet obstruction, bladder exstrophy and as a consequence of urinary contamination of the vagina in association with incontinence and prolonged maintenance of recumbent posture. [1,3,5,6,9].

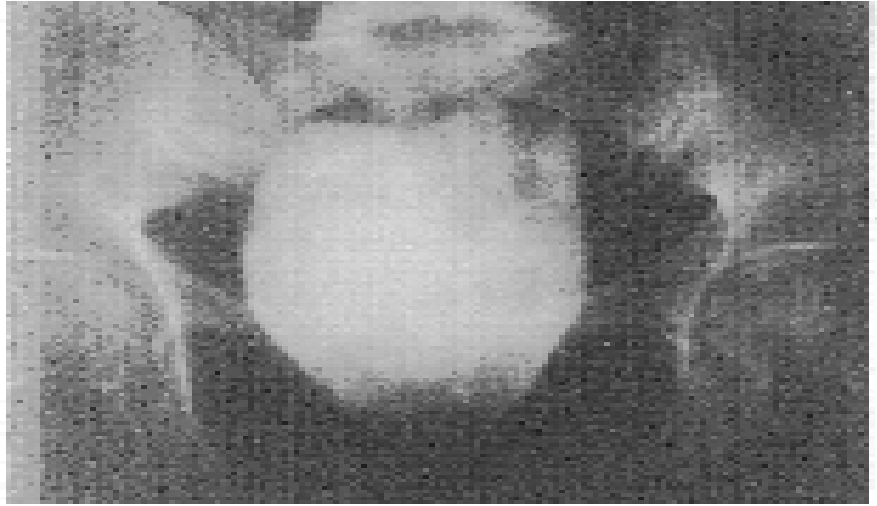
Primary vaginal stones are extremely rare and are often mistaken for bladder calculi on plain radiography. However, intravenous pyelography and sonography can help differentiate between the two. (2004 May; 32(4): 204-6.) To our knowledge, only one case has been reported in which there was development of a large vaginal stone in a 25-year-old female, correlated with vesicovaginal fistula. The stone, composed of struvite and carbonate apatite, formed around non-absorbable surgical suturing material in urine with urease producing (*P. mirabilis*) bacterial infection. The stone was removed by simple lithotripsy technique (Lukacs T, Mohammed S. *Orv Hetil.* 1989 Nov 19;130(47):2537-8). Sometimes the stone may be fragmented by lithotripsy before the extraction. The associated etiology should be treated concomitantly in order to prevent recurrence. (Garcia Ligerio J, Tomas Ros M, Navas Pastor J, Garcia Garcia F, Sempere Gutierrez A, Rico Galiano JL, Fontana Compiano LO. *Actas Urol Esp.* 2001 Sep;25(8):582-5.)

Primary vaginal stones are a rarely reported complication of a congenital vaginal septum, an imperforated or micro-perforated hymen, vaginal scarring or female circumcision [8]. They have also been reported after abdomino-perineal resection for carcinoma of rectum [11].

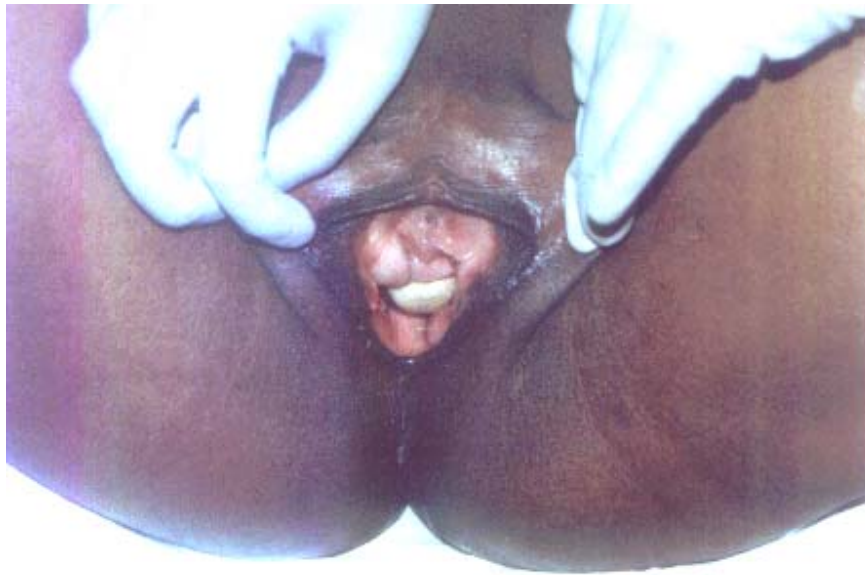Secondary vaginal stones have been reported in the formation of a vaginal calculus around the thread of a Copper T-device [7], and around inadvertently unremoved medical gauze in a patient with vesico-vaginal fistula. (van Oorschot FH, Mallens WM, van Helsdingen PJ. *Diagn Imaging Clin Med.* 1986; 55(3): 157-60).

Vesico-vaginal fistula is an uncommon problem in the developed world. The primary cause of vesico-vaginal fistula in the United States is related to gynecologic surgery. In a series of 303 women with genitourinary fistula by Lee et al., fistulas were related to gynecologic surgery in 82%, obstetric events in 8%, radiation therapy in 6%, and trauma or fulguration in 4% (Lee RA, Symmonds RE, Williams TJ. *Current status of genitourinary fistula. Obstet Gynecol* 1998; 72: 313-315).

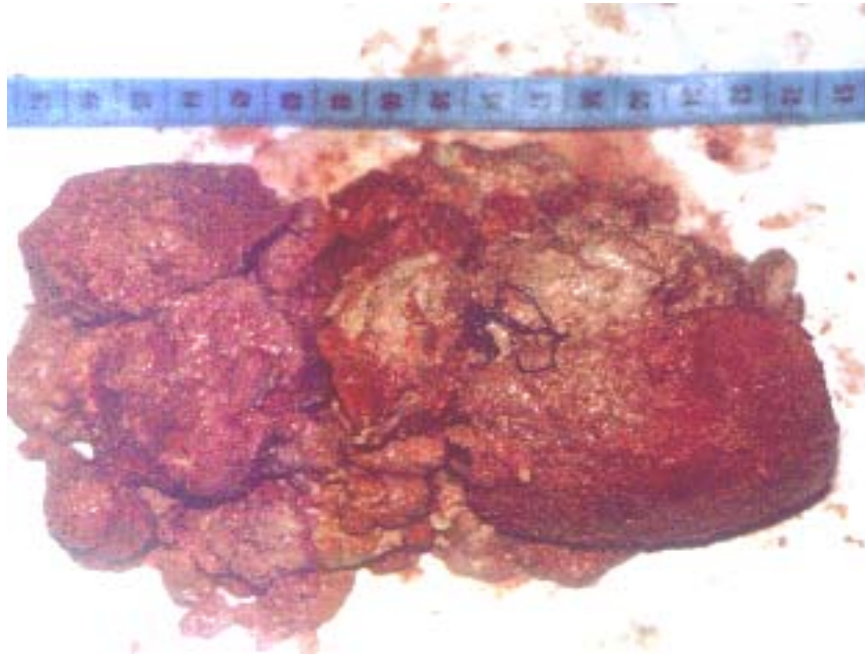
In developing countries vesico-vaginal fistulas are more common and are related to obstructed labor due to unattended deliveries, small pelvic dimensions, malpresentation, poor uterine contractions and introital stenosis. Although the exact incidence of vesico-vaginal fistula in the United States is unknown, estimates range between 0.01 to 0.04% of gynecologic procedures. Rare causes of VVF include lymphogranuloma venereum, tuberculosis, syphilis, bladder stones, retained foreign body in the vagina, and trauma. Spontaneous vesico-uterine fistula has also been reported as a rare complication following uncomplicated vaginal birth after Caesarean section. (Miklos JR, Sze EHM, Parobeck D, et al. *Vesicouterine fistula: a rare complication of vaginal birth after Caesarean. Obstet Gynecol* 1995; 86: 638-639). Most commonly, vesico-vaginal fistulas in developing countries are associated with benign gynecologic surgery, especially hysterectomy, and are caused by extensive dissection between the bladder and the uterus, unrecognized bladder laceration, inappropriate stitch placement, and/or devascularization injury to the tissue planes. Concurrent ureteric involvement has been reported to be as high 10-15% of vesico-vaginal fistula cases. Patient risk factors, which may predispose to development of vesico-vaginal fistula, include prior pelvic surgery, history of PID, pelvic malignancy, endometriosis, infection, diabetes, and anatomic distortion. The presence of these risk factors should be considered pre-operatively and patients counseled accordingly.



Pic.1: X Ray Pelvis showing Big Opacity in the pelvis



Pic. 2: Vaginal stone visible on examination at the vaginal outlet.



Pic. 3: Vaginal stone after removal with prolene suture.

REFERENCES:

1. Raghavaiah NV, Devi AI. J Urol. 1980 May;123(5):771-2.0.
2. Garcia Ligerio J, Tomas Ros M, Navas Pastor J, Garcia Garcia F, Sempere Gutierrez A, Rico Galiano JL, Fontana Compiano LO. Actas Urol Esp. 2001 Sep;25(8):582-5.
3. Barbagli G, Selli C, Masini G, Carini M, Lenzi R. Ital J Surg Sci. 1985; 15(1): 85-8.)
4. Petrillo CR, Borrelli M, Botelho C. Arch Phys Med Rehabil. 1981 May; 62(5): 227-9.
5. Malhotra N, Kumar S, Roy KK, Agarwal R, Verma V, J Clin Ultrasound. 2004 May; 32(4): 204-6.
6. Eyk NA, grover S, Fink AM. J Pediatr Adolesc Gynecol. 2003 Oct; 16(5): 285-7
7. Dube S., J Obstet Gynaecol India. 1979 Jun; 29(3): 711-2.
8. Ergun SS, Babalioglu R, Aydin S, Ozmen N, Sidal B, Koser RM. Arch Gynecol Obstet. 2002 Jan; 266(1):58-9. Horiguchi A, Hatakeyama N, Ikeuchi K. Hinyokika Kiyō. 1998 Jul; 44(7): 521-3.
9. Yoshimura T, Nagata Y, Matsuura K, Okamura H. Gynecol Obstet Invest. 2000; 50(1): 64-6.
10. Segawa N, Katsuoka Y, Kaneda K. Hinyokika Kiyō. 1998 Jul;44(7):517-20.
11. Dhall JC, Goel R, Marwah S. Urol Int. 1997; 58(3): 197-8.

AUTHORS

- **J Arshad**
Consultant Urological Surgeon
Aziz Fatimah Trust Hospital &
Associate prof. of urology
Madina University Faisalabad.
- **S Sultana**
Senior Registrar Gynecology,
Allied Hospital Faisalabad.
- **F Mahmood**
Registrar Urology
Aziz Fatimah Trust Hospital,
Faisalabad.